

CLINICAL APPLICATION OF SPECTROPHOTOMETRIC INTRACUTANEOUS ANALYSIS

Marc Moncrieff¹, Symon Cotton², Ela Claridge³, Per Hall¹

¹ Addenbrooke's Hospital, Cambridge, UK; ² Astron Clinica Limited, UK; ³ University of Birmingham, UK.

ABSTRACT:

Spectrophotometric Intracutaneous Analysis (SIA) is a rapid, non-invasive scanning technique where a SIAscope is used to analyse light reflected from the skin in the visible and infrared spectra. Complex algorithms return SIAgraphs that contain high-resolution information regarding the in vivo epidermal and dermal melanin, vasculature and the collagen content of the papillary dermis within the lesion. A dataset of 330 assorted pigmented lesions have been analysed to date that includes 55 melanomas.

Melanomas characteristically display combinations of the following features: (1) An 'erythematous blush' at the invading margin of the superficial spreading lesion; (2) displacement of blood in the papillary dermis by invasive regions; (3) tumour punching holes in papillary collagen; (4) collagen arranged into rosettes and whorls around invasive nodules; (5) dermal melanin in haphazard arrangements in invasive regions. In contrast, benign naevi display a regular arrangement of dermal and epidermal melanin, a homogeneous vascular pattern and a homogeneous collagen arrangement.

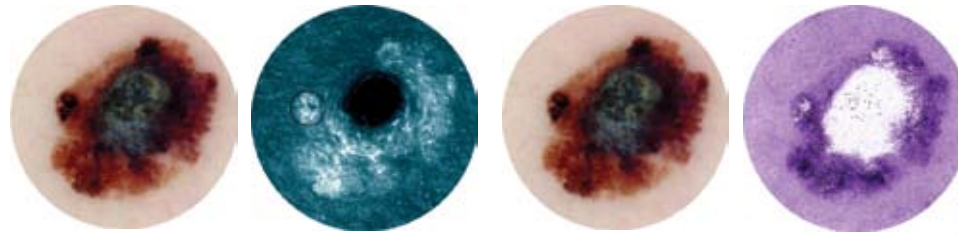
Using the SIAscope, these new features identified in melanomas have been shown to be reliable and repeatable. As expected when applying them to the diagnosis of melanoma, some of these features show a high specificity (84.8%) and whilst others a high sensitivity (96.1%). However, on combining them using logistical regression analysis a sensitivity of 88.5% and a specificity of 72% can be achieved. In addition receiver-operator curves constructed from these data can be shown to improve diagnostic performance when compared to dermatoscopy.

This unique information could be used to assist in the diagnosis of naevi and early malignant melanoma. Further on, this study will identify and assess features obtained using SIA technology and provide specificity and sensitivity to guide the physician in planning the management of their patient.

CONCLUSION:

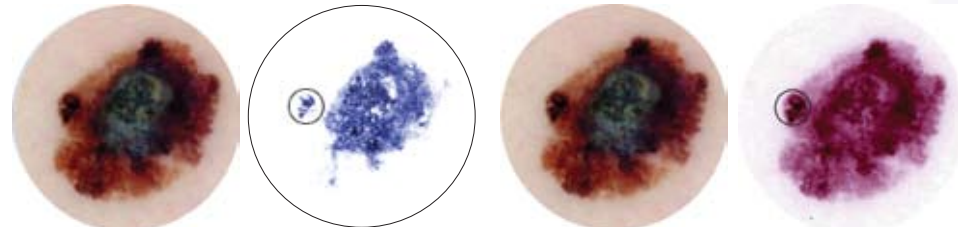
SIAscopy is a technique that can be effective for investigating pigmented skin lesions. It must be emphasised that the features assessed here were chosen because of their simplicity, reliability and repeatability and can be identified by clinicians and non-clinicians alike after minimal training. In addition, no dermatoscopic information was used in this trial so that purely SIAscopic features were assessed. ROC curves (fig 2) show SIAscopy outperforming clinicians assessing lesions after formal training in dermatoscopy. It is expected that in the future the inclusion of dermatoscopic criteria, the identification of additional SIAscopy features and widening experience in this technique will serve to improve diagnostic accuracy of physicians assessing pigmented skin lesions still further.

Superficial spreading melanoma with nodular component



SIAgraph: Collagen in papillary dermis
White = High collagen concentration
The invasive nodule has punched a hole in the collagen layer as has the early invasive component peripherally (circled). At the periphery, the immunocytic response to the early invasive region has produced fibrosis seen as whorls and rosettes.

SIAgraph: Blood in papillary dermis
Red = High haemoglobin concentration
The invasive nodule has displaced the blood supply from the papillary dermis.
Immunocytic reaction has produced vasodilation seen as a peripheral "erythematous blush".



SIAgraph: Melanin in papillary dermis (blue areas)
The dermal melanin is asymmetrically distributed in large contiguous regions. The central region correlates well with the blue-grey veil seen on the digital ELM view. Note the early invasion picked up in the periphery (circled).

SIAgraph: Melanin in epidermis and papillary dermis
Many SIAscopy features are histopathologically due to melanin. This SIAgraph shows only melanin to allow easy identification of features such as radial streaming (circled).

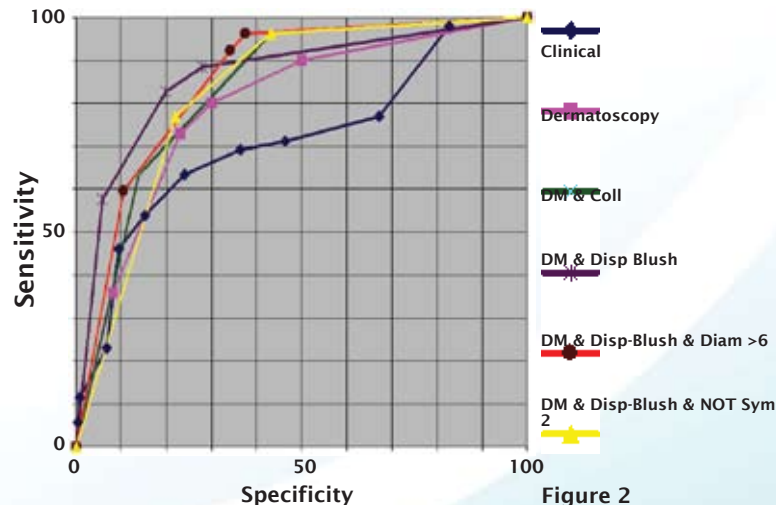


Figure 2

Figure 2:

ROC curve for combinations of SIAscopic features as determined using logistic regression analysis. The closer the line is to the upper-left corner the better the test. Most combinations of SIAscopy features outperform the ROC curve for dermatoscopy (redrawn from Binder et al., 1997) and all techniques greatly outperform the 7-point checklist (clinical examination).

REFERENCES:

Binder M, Poespoeck-Scwarz M, Steiner A et al. (1997) Epiluminescence microscopy of small pigmented skin lesions: short-term formal training improves the diagnostic performance of dermatologists J Am Acad Dermatol : 36, 2(1); pp. 197-202

MacKie R (1990) Clinical recognition of early invasive melanoma Brit Med J, 301: pp. 1005-6

Acknowledgements: Research funded by EPSRC