

SIASCOPE AS A POSSIBLE ADJUNCT TO DERMATOSCOPY

R. Schiffner¹, U. Lepski¹, M. Moncrieff², S. Cotton³

¹Department of Dermatology, University of Regensburg, Germany, ²Addenbrooke's Hospital, Cambridge, UK and ³Astron Clinica, UK

ABSTRACT:

The SIAScope is a device which examines a 12mmx12mm area of in-vivo skin returning information regarding its structure and composition. It utilizes spectral bands of light including visible and infrared returning SIAGraphs showing the distribution and quantity of: collagen within the papillary dermis; blood; melanin and the presence of melanin in the papillary dermis.

The differential diagnosis of pigmented skin lesions under the dermatoscope is necessarily subjective and operator dependent relying on the visual interpretation of a colour dermatoscopy image. By separating out the individual components of the skin the SIAScope may reduce the subjectivity and training required for this analysis.

Step 1 of the conventional algorithm described by Stolz et al. determines whether any of the structural components "pigment network", "pigmented aggregated globules" or "branched streaks" are present. As these structures are formed from the distribution of the pigment melanin their investigation using the melanin SIAGraph allows their examination free from the background components of the skin. The presence of these features indicates a melanocytic lesion.

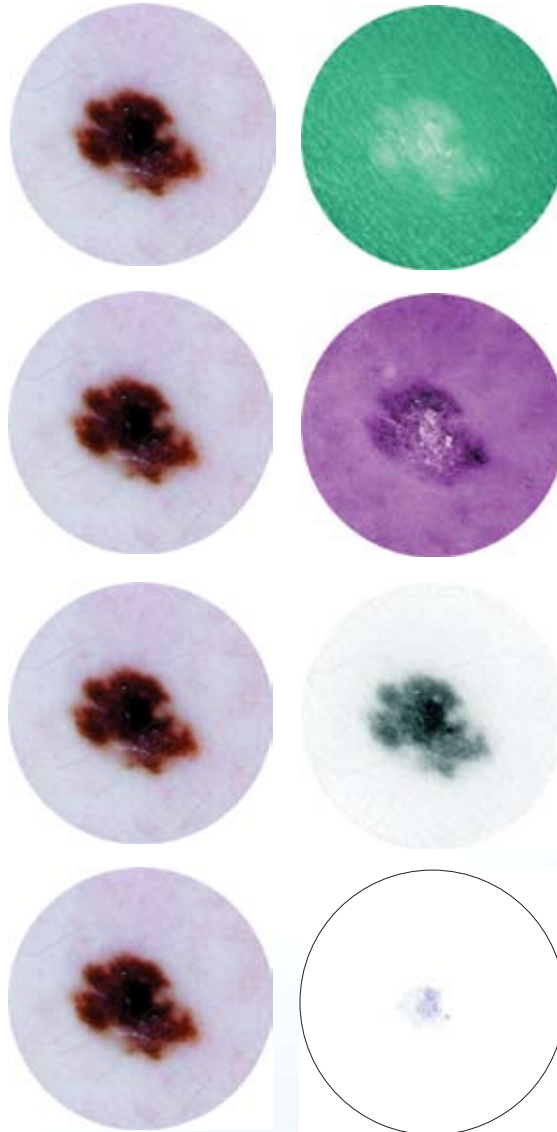
Step 2 investigates the presence of "steel-blue" pigmentation typical of a blue naevus consistent with melanin within the papillary dermis. Such structures can be clearly seen by examining the dermal melanin SIAGraph where dermal melanin should be seen filling the entire lesion.

Step 4 investigates the presence of "red, blue-red and red-black lagoons" typical of haemangioma and angiokeratoma. Such lagoons being formed of blood show up very clearly in the blood SIAGraph allowing their differentiation from a melanocytic lesion.

CONCLUSION:

In conclusion the examination of separate components of the skin as provided by the SIAScope may enhance dermatoscopic diagnosis. Moreover, more detailed image analysis of the SIAScope images may elucidate further subvisual criteria for recognition of malignant melanoma.

6mm Diameter Melanoma



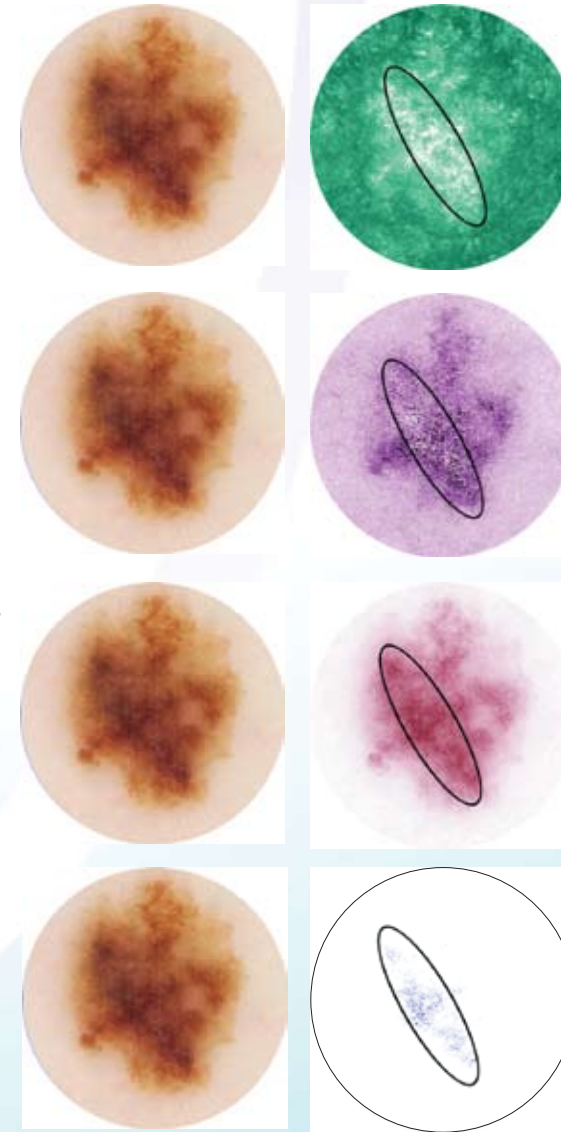
SIAGraph: Collagen in papillary dermis (White = more)
Note fibrosis in centre of lesion.

SIAGraph: Blood in papillary dermis
Note displaced blood and erythematous blush.

SIAGraph: Total melanin
Blood and other pigments are removed to give a clearer view of melanin features.

SIAGraph: Melanin in papillary dermis
Blue areas mark melanin in papillary dermis.

4mm Diameter Melanoma - Features of interest circled



SIAGraph: Collagen in papillary dermis (White = more)
Note fibrosis in centre of lesion.

SIAGraph: Blood in papillary dermis
Note displaced blood and erythematous blush.

SIAGraph: Total melanin
Blood and other pigments are removed to give a clearer view of melanin features.

SIAGraph: Melanin in papillary dermis
Blue areas mark melanin in papillary dermis.